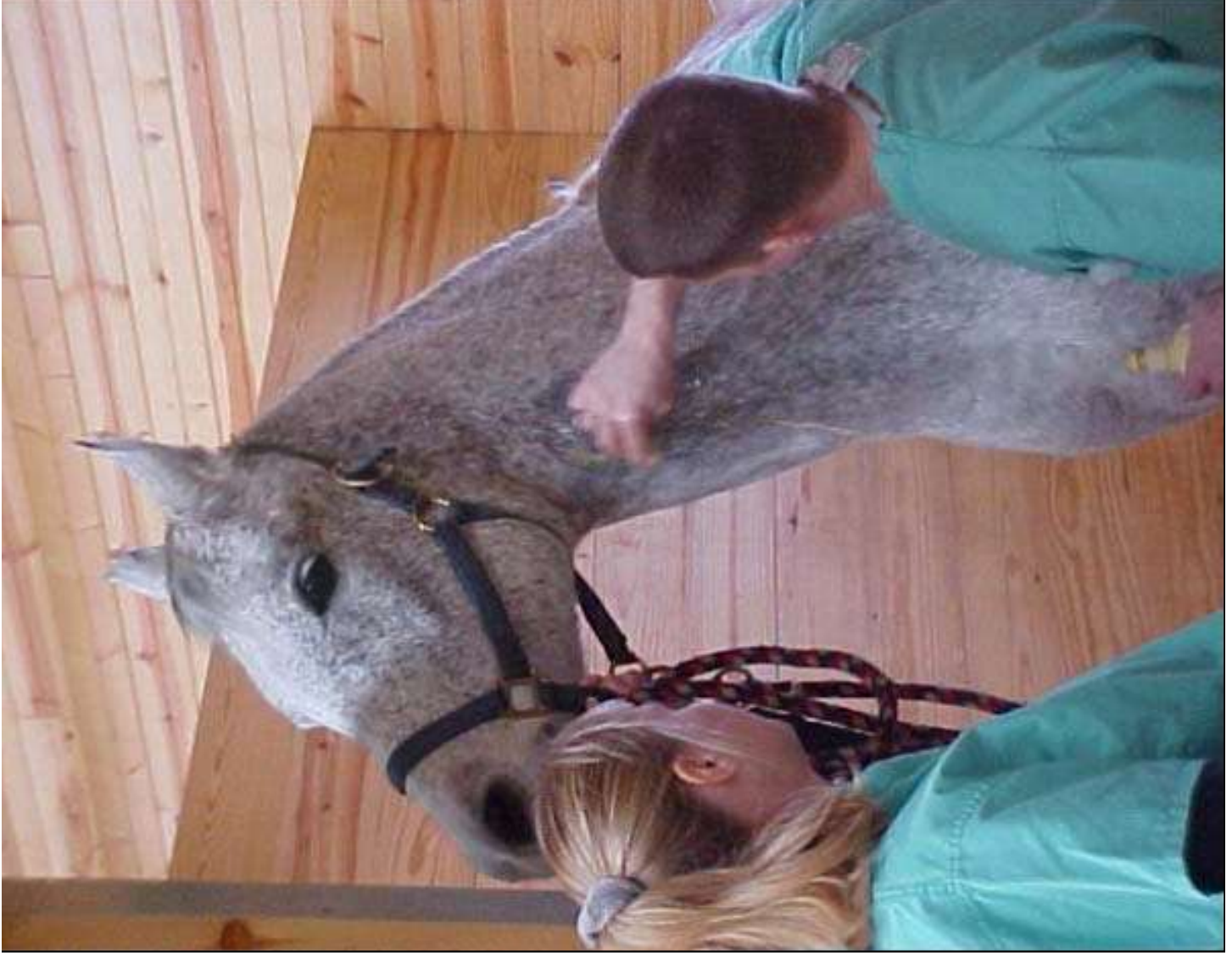



Procedure:
Removing a tumor from
inside this horse's mouth.





Fold out wall in surgery suite supports horse until ready to lay down.



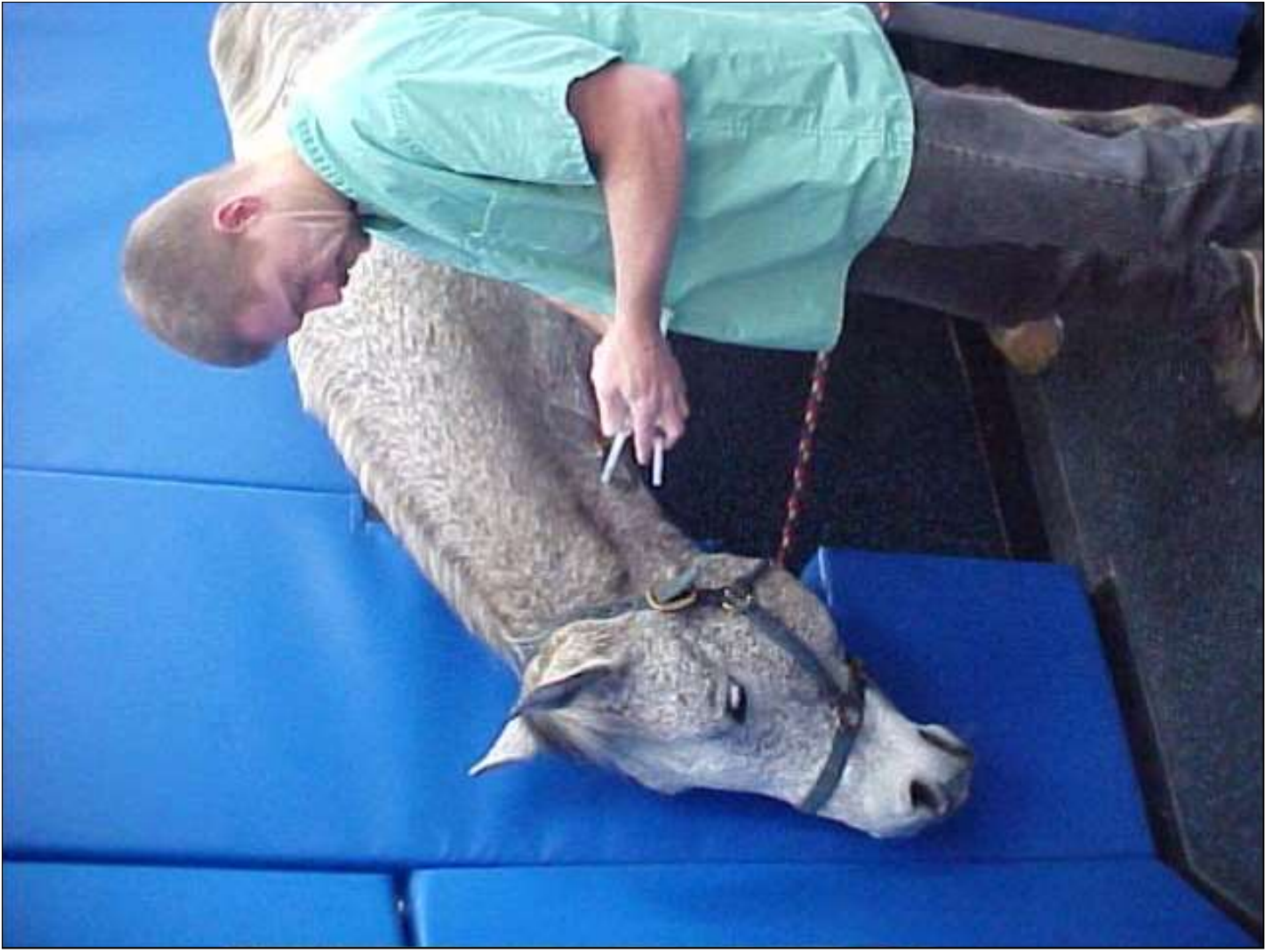

Jon and Tammy monitor anesthesia.



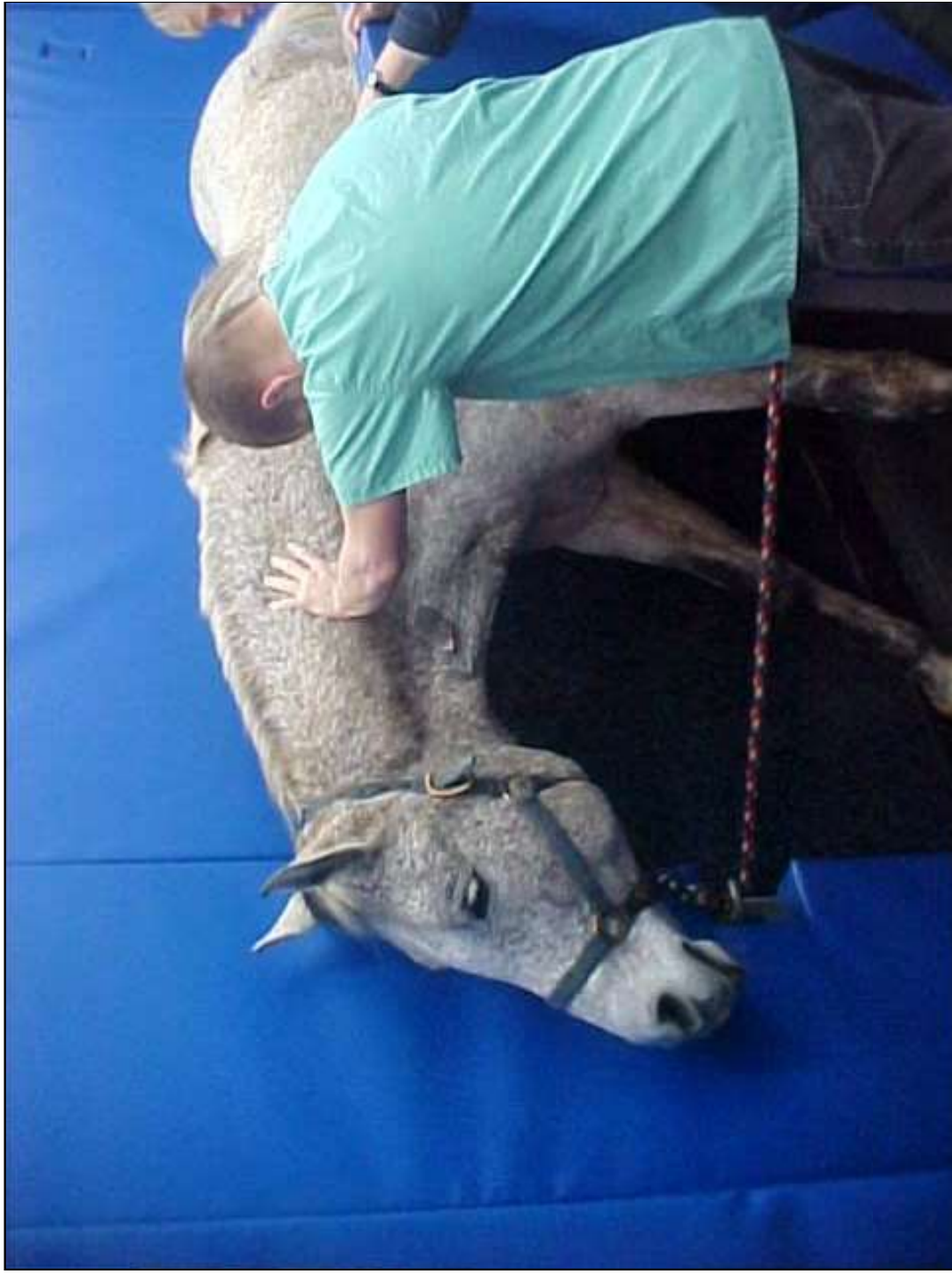

The horse is almost out....





He starts to sit back, safely supported by the folding wall,
Jon and Tammy.





He sinks slowly down to rubber floor.





Jon supports his head, while Tammy swings the wall back so the horse can roll over on his side.





The wall is out of the way, and the horse is ready to roll onto his side.





Now he is really out, and Tammy prepares meds for surgery. We cover his eye with a towel to shield him from light and 'scary sights.'





Tammy administers more meds via the IV placed during surgery prep.



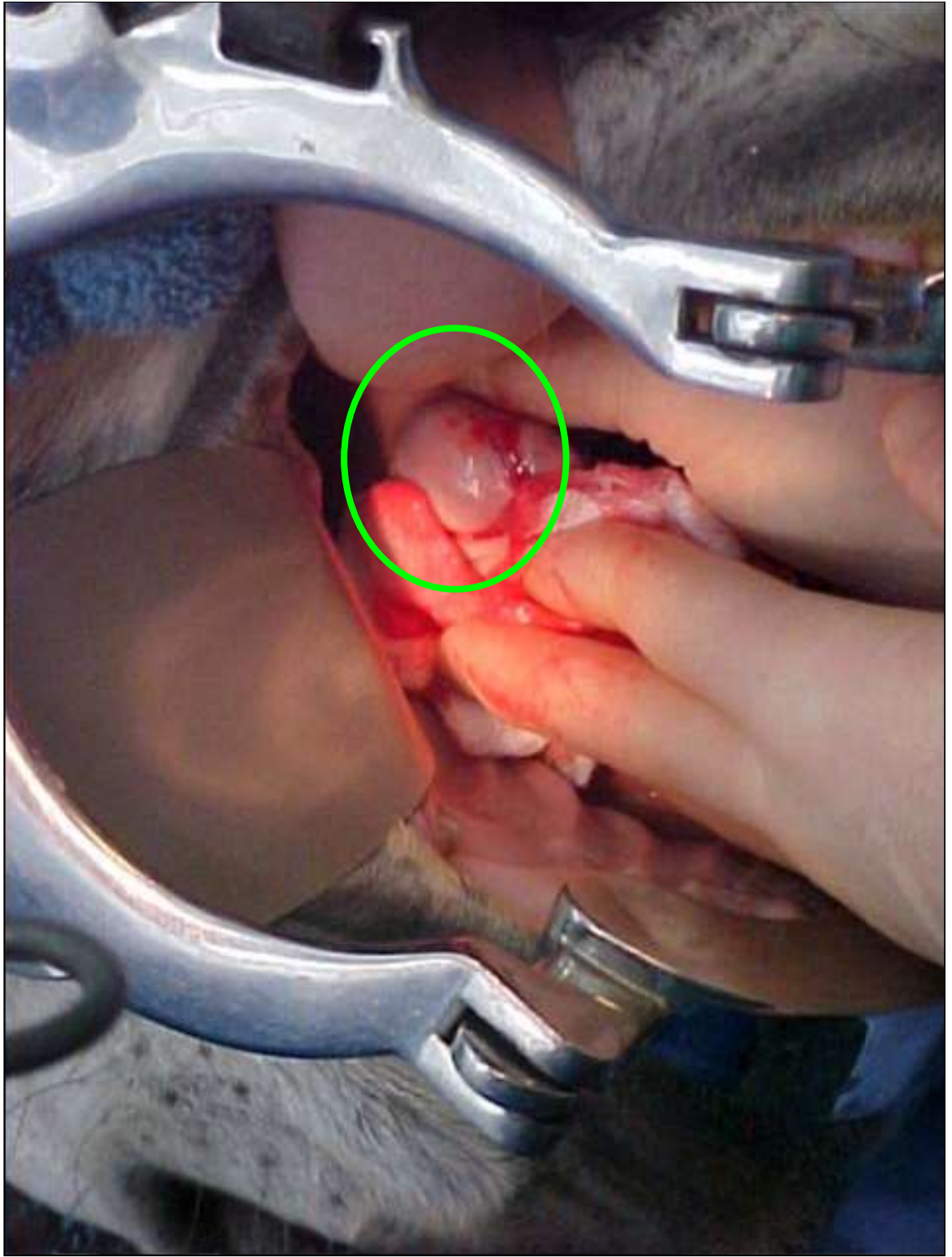


We place the speculum on his head so we can operate in his mouth. We also cushion his head and position it correctly using an inflatable 'pillow' and pad his face with towels so the speculum bars don't bruise or injure his face.



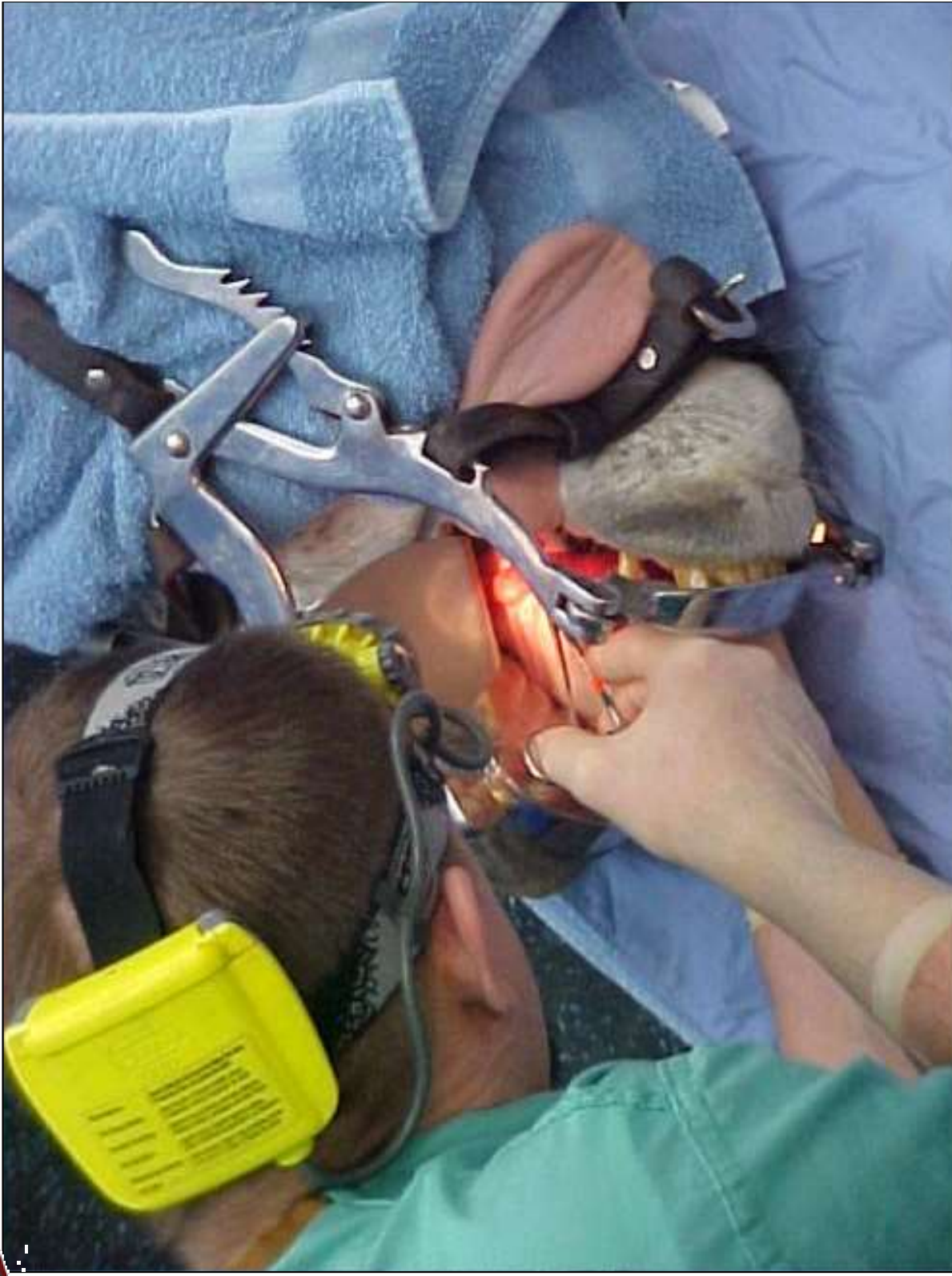

Here is the tumor – about the size of a golf ball.



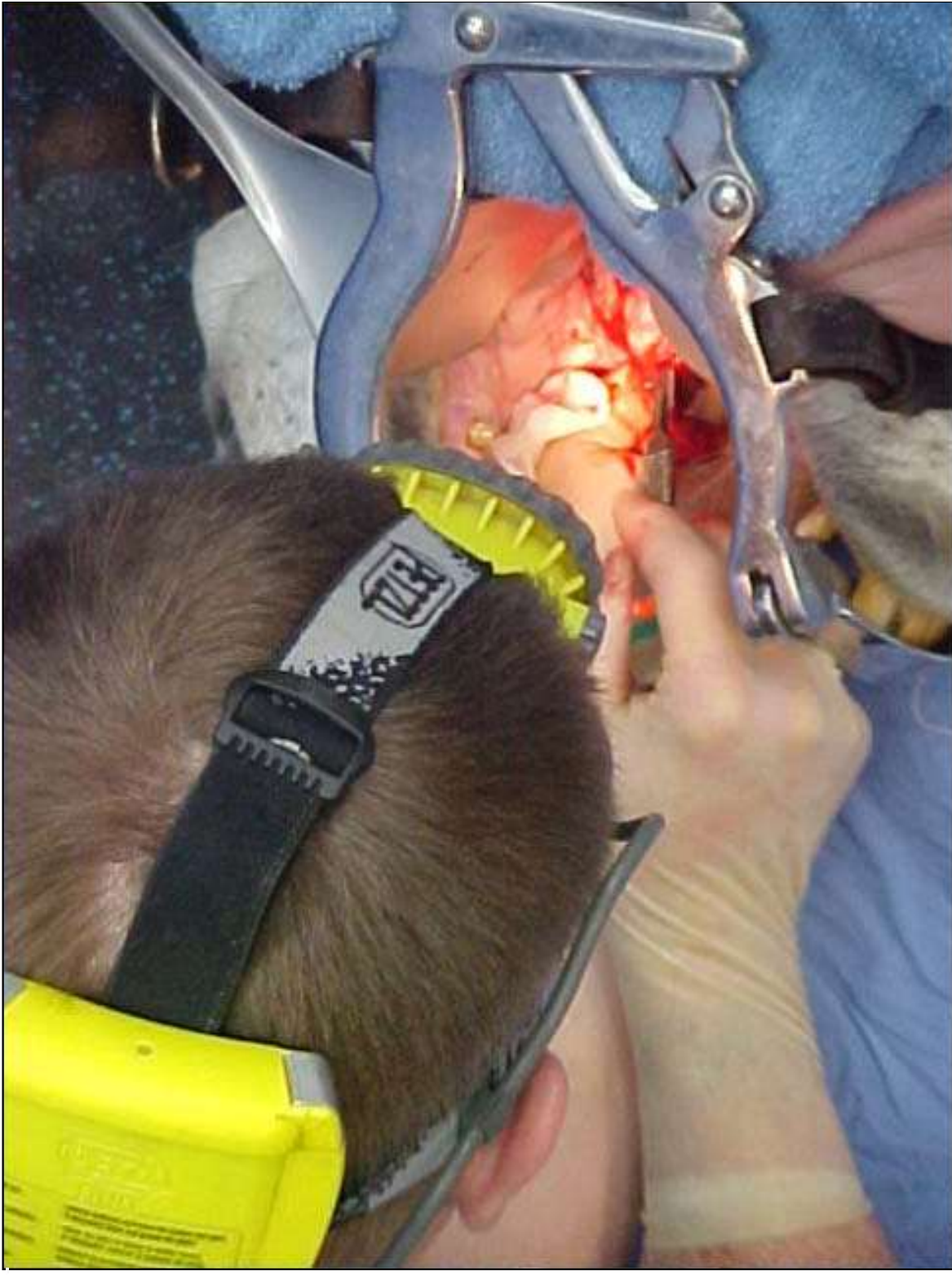

Dr. Gieche starts to remove the tumor. He's able to do this from the inside of the mouth, instead of the outside of his cheek.



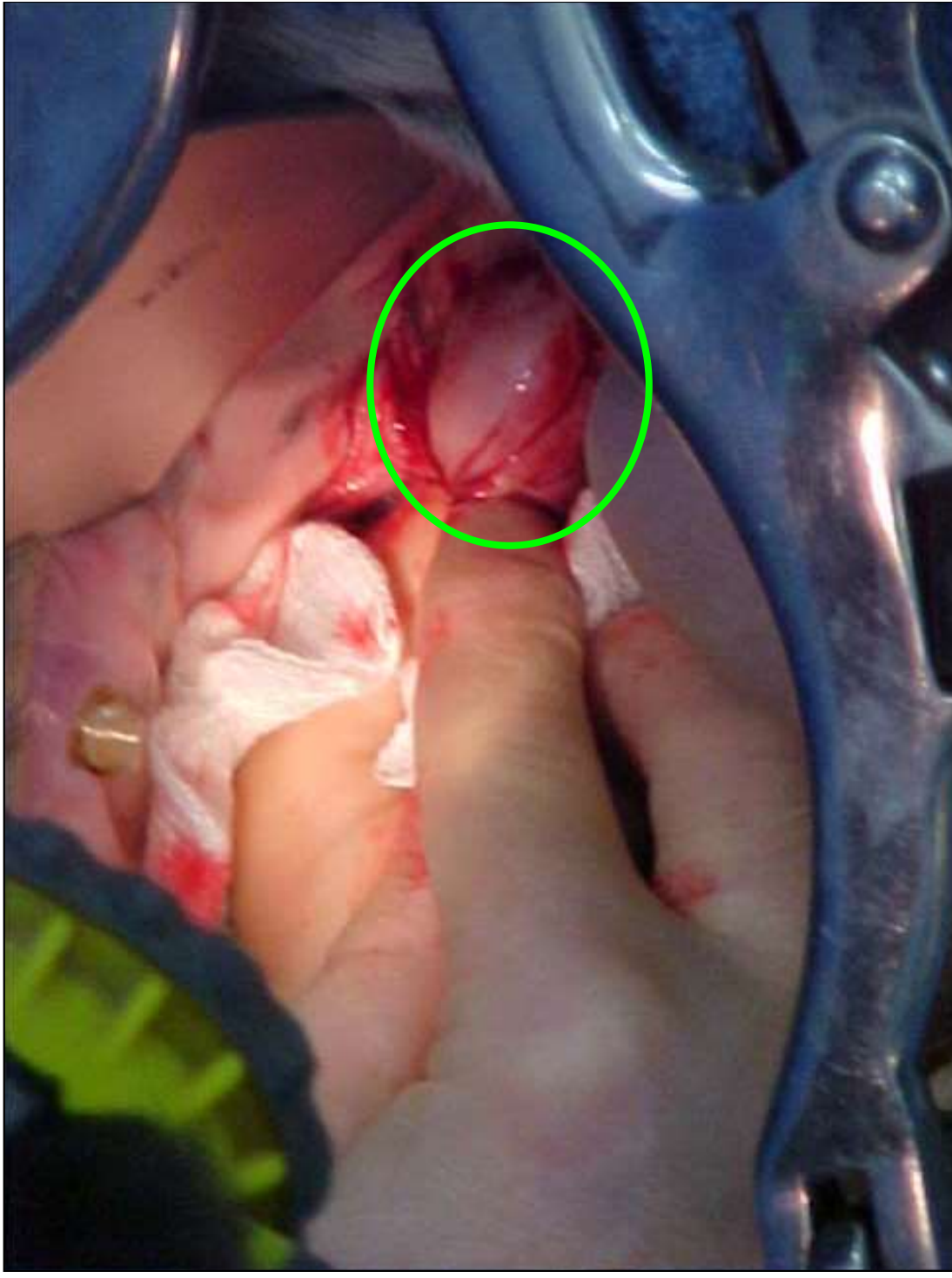


It's delicate work, because the tumor is fed by many blood vessels (which we don't want to cut), and because it's hard to move around in the tiny space available.



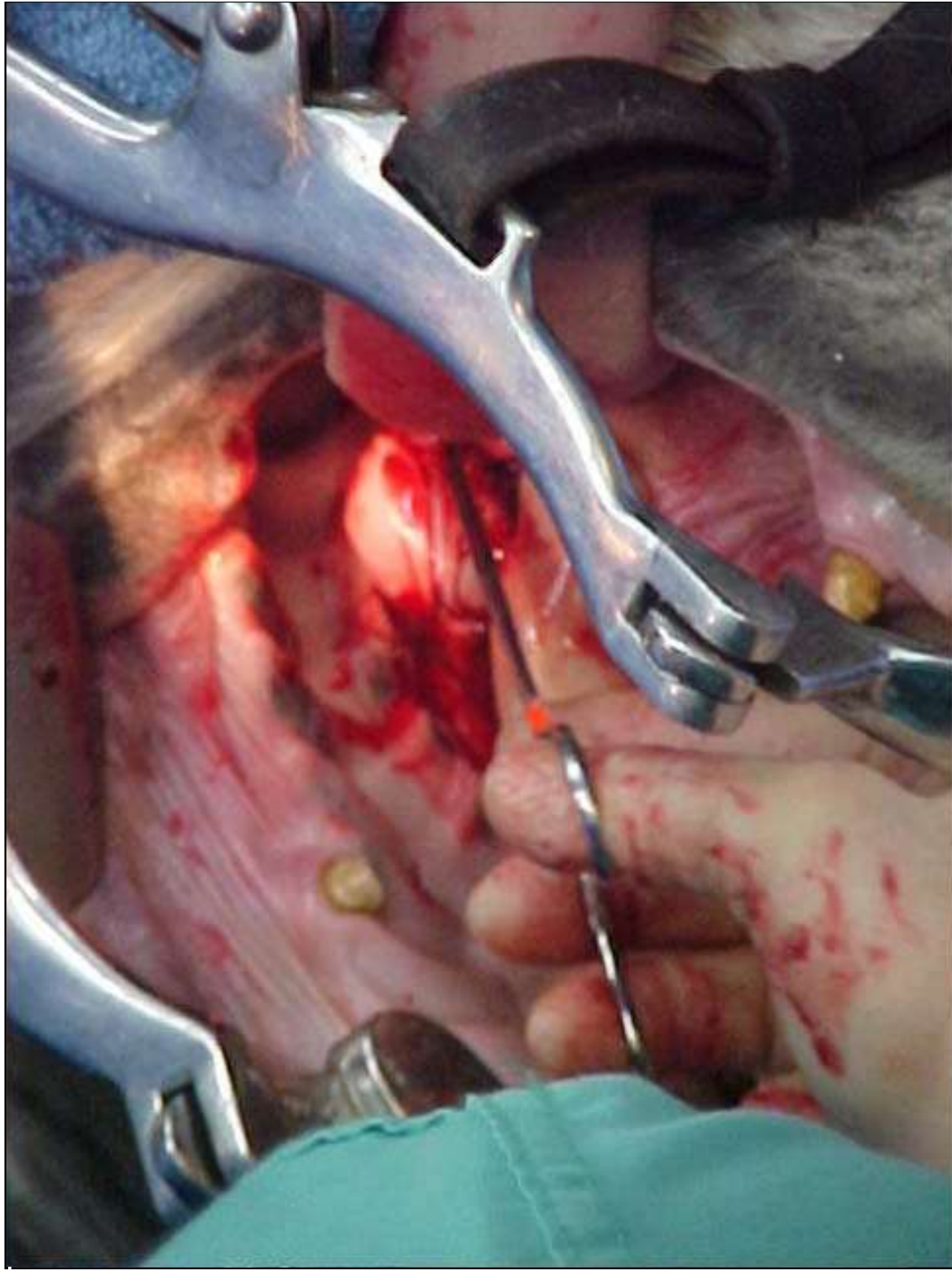


The tumor is slowly coming free.



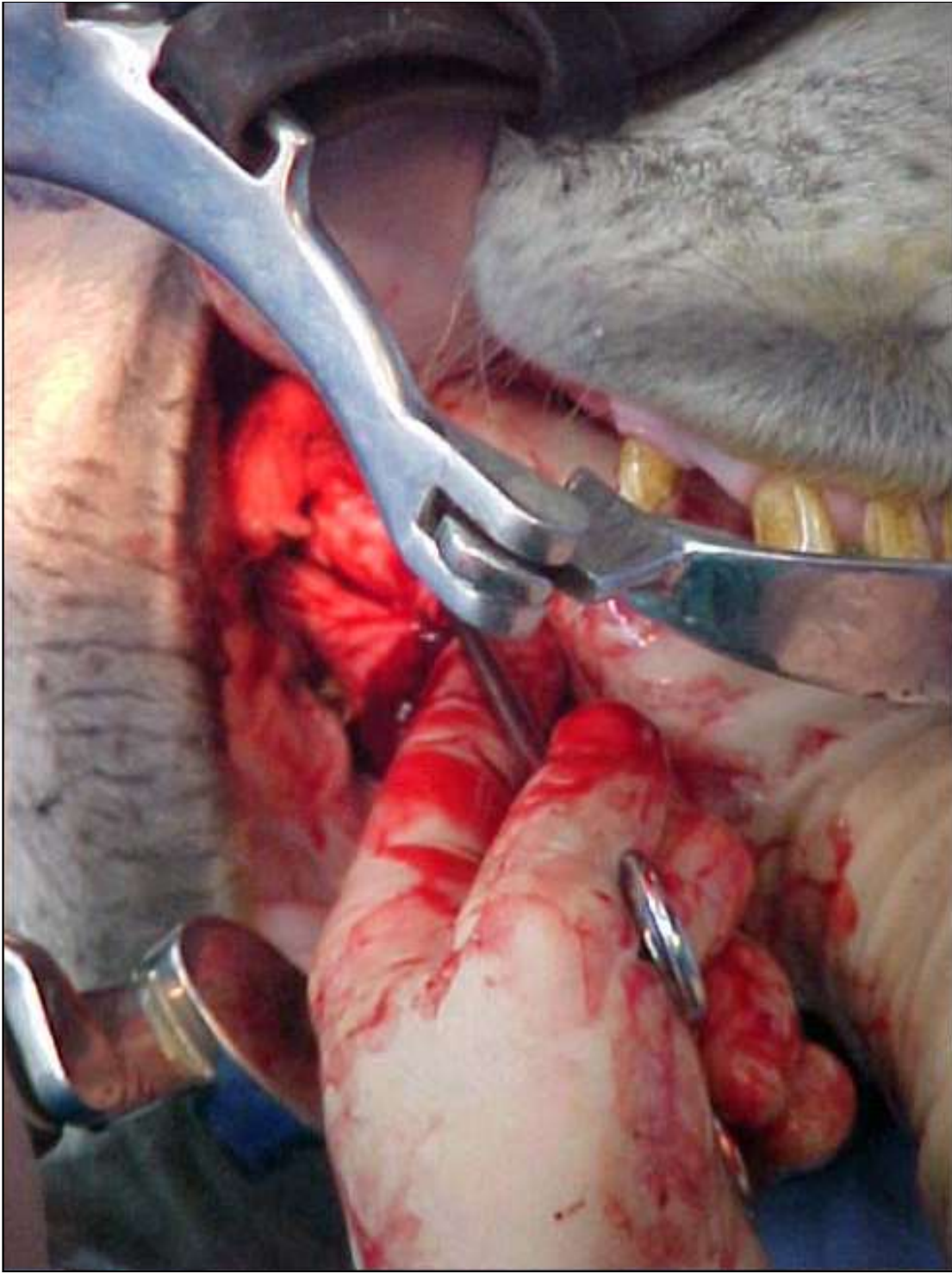


About half-way there....



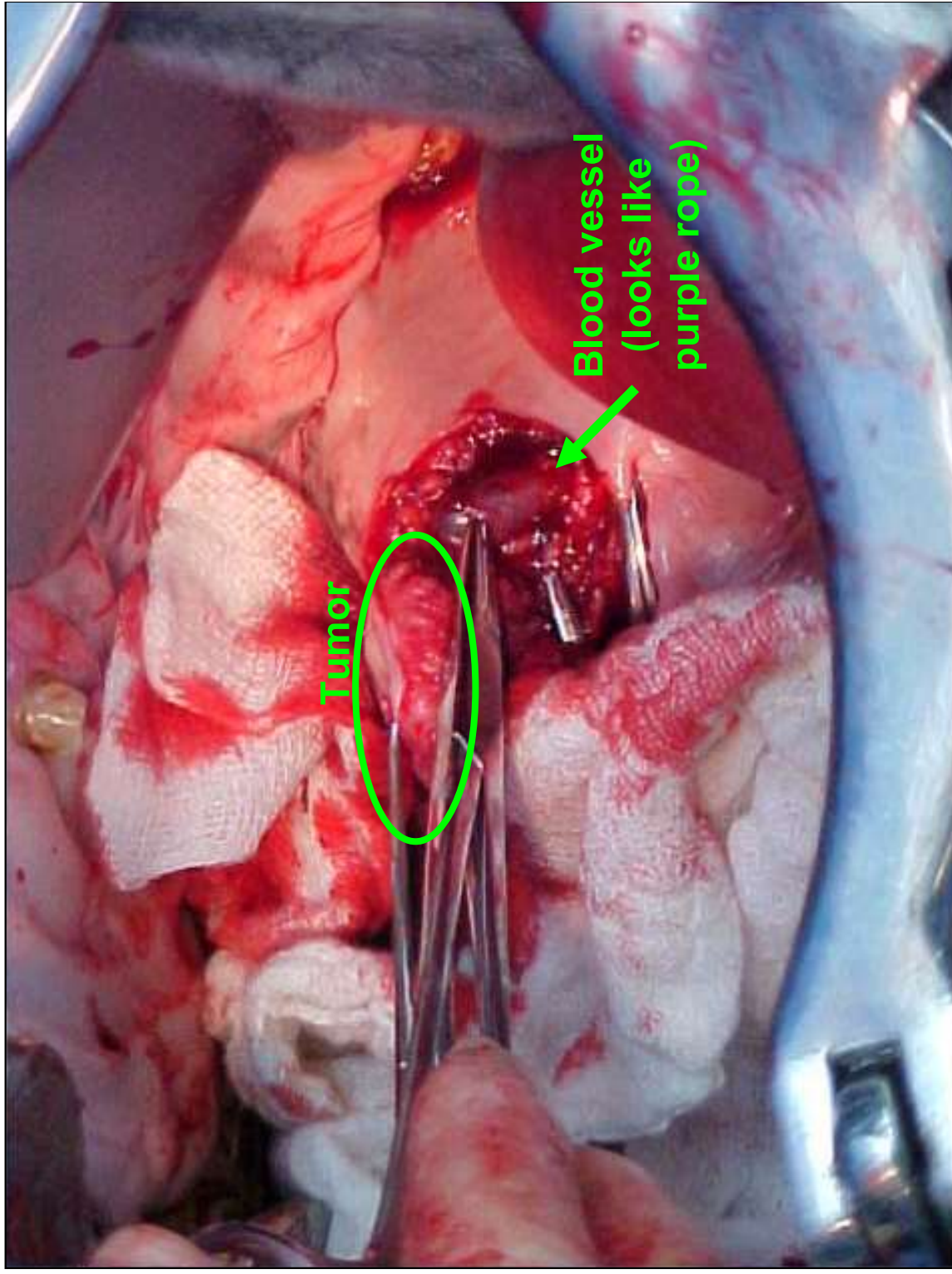


A little more...





Here's the tumor – but look what it was sitting on! A very large blood vessel was supplying this tumor. Dr. Gieche needs to carefully avoid cutting this while he removes the rest of the tumor.



Tumor

Blood vessel
(looks like
purple rope)



The tumor is gone! This area will fill in with granulated tissue after some suturing is done.
The tumor is examined, and sent for a biopsy. If benign, this horse's prognosis is excellent!

